






In vivo test of acute exposure of polyethylene microplastics on kidney and liver of *Rattus norvegicus* Wistar strain rats

Awaluddin Hidayat Ramli Inaku^{1,2*} , Hadiyanto Hadiyanto³ ,
Henna Rya Abdurachim⁴ , Tahyatul Bariroh⁵ , Siti Rachmawati⁶ 

¹ Department of Doctoral Environmental Science, Faculty of Postgraduate, Diponegoro University, Semarang, 50275, Indonesia

² Department of Public Health, Faculty of Health Sciences, Universitas Muhammadiyah Prof. Dr. Hamka, Jakarta, 12210, Indonesia

³ Department of Chemical Engineering, Faculty of Engineering, Universitas Diponegoro, Semarang, 50275, Indonesia

⁴ Department of Pharmacy, Faculty of Medical, Universitas Diponegoro, Semarang, 50275, Indonesia

⁵ Pharmacy and Sciences Faculty, Universitas Muhammadiyah Prof. Dr. Hamka, Jakarta, 12210, Indonesia

⁶ Department of Environmental Science, Faculty of Mathematics and Natural Sciences, Sebelas Maret University, Surakarta, 57126, Indonesia

* Corresponding author's e-mail: awalhidayat@uhamka.ac.id

ABSTRACT

The increasing use of plastics has caused severe environmental pollution, especially microplastics with plastic particles with a diameter of 5 mm or less. These particles are formed by environmental factors such as weathering and ultraviolet radiation, worsening environmental pollution. This environmental pollution increases human exposure to microplastics through the food chain. Many studies have reported the adverse effects of microplastic exposure on food and aquatic organisms. However, relatively few studies have used white mice. The entry of microplastics into white mice can affect two essential organs, namely the liver and kidneys. In this study, we conducted in-vivo experimental tests on male white mice by exposing them to a single dose of pure PE (polyethylene) type microplastics and then observing them for 14 days. Toxicological effects were evaluated comprehensively in white mice by examining clinical signs, body weight, and kidney and liver function activity through blood tests for creatinine, SGOT, and SGPT parameters. Further kidney and liver abnormalities were analyzed through histopathological tests. Based on the results of experiments carried out, it was found that PE-type microplastics had a significant impact on changes in body weight, increased functional activity of the kidneys and liver in white mice as well as chronic histopathological abnormalities in male white mice, so it is hoped that this research can clarify that PE type microplastics can affect kidney and liver organs for those who consume large amounts in a short time.

Keywords: acute, poltethylene, kidney, liver, in vivo.

INTRODUCTION

Indonesia is the world's second-largest contributor of plastic waste after China (Sincihu, 2022). Global plastic production has increased dramatically over the past few decades, rising from 1.5 million metric tons in 1950 to 390.7 million metric tons in 2021, and further increases in production and use are expected (Statista Research Department, 2023). Plastics are widely

used in various fields because of their desirable properties, such as low cost, high durability and strong plasticity (Reddy et al., 2013). Synthetic polymers (plastics) from fossil resources are produced in large quantities and end up in the environment as microplastics, which, if disposed of incorrectly, can impact flora, fauna and humans (Saha et al., 2023). The most commonly produced polymer types are polyethylene (PE), polypropylene (PP), and polystyrene (PS), with

a microplastic fraction intentionally produced, generally defined by a particle diameter of less than 5 mm (EFSA 2016) (Opinion, 2011). Microplastics (MPs) are plastic particles with a particle size of less than 5 mm and come from any plastic (Hou et al., 2021). Microplastics are produced through two main sources, namely: (1) manufactured products that contain plastic particles or powder, such as cosmetics, detergents, sunscreen, and pharmaceutical vectors (Cole et al., 2015). (2) greater plastic decomposition through UV radiation, mechanical abrasion, and environmental biological degradation (Andrady, 2011).

Microplastics are a significant environmental health problem and an increasing source of concern (Deng et al., 2017). Various human activities, domestic, industrial and coastal, cause these dangerous plastic fragments in ecosystems (land and water). MPs have diverse chemical compositions, including polystyrene (PS), polyvinyl chloride (PVC), polyethylene (PE), polypropylene (PP), and polyethylene terephthalate (PET), etc. (Shen et al., 2023). Polyethylene is the main source of microplastics widely and dominantly present throughout the environment (Uurasjärvi et al., 2021). There are types of MPS including their uses, namely polyethylene (polytene; PE) in the form of low-density (LDPE: trash bags, films) and high-density construction (HDPE; shopping bags, bottle caps) or tetraphthalate (PET: bottles, food trays), polypropylene (PPL: cubes, straws), polyvinyl chloride (PVC: pipes, door and window frames), and polystyrene, both rigid (PS: food pots, toys) and expanded (EPS: packaging, insulation) (Vianello et al., 2019). Land and aquatic biota interact with plastics in the environment, giving rise to widespread concern about negative ecological impacts (Banerjee and Shelver, 2021). Humans can be exposed to MPs through various pathways in daily life, such as ingestion, inhalation, and skin contact (Zhang et al., 2024).

Plastic ingested by organisms can bioaccumulate and reach humans via trophic transfer in the food chain (Nelms et al., 2018; Guo et al., 2020; Kik et al., 2020). In addition to being able to cross the intestinal epithelium and enter other tissues via the bloodstream (Yee et al., 2021), several studies have reported the discovery of MPs in human blood (Leslie et al., 2022) and organs, including liver, kidney, intestine, lung, and liver. lungs, and placenta (Amato-Lourenço et al., 2021; Ragusa et al., 2021; Horvatits et al., 2022; Nugrahapraja et al., 2022). Therefore, the potential toxicity and

health hazards of MPS require further attention. Previous research has shown that the accumulation and distribution of MPs in aquatic organisms is species-specific and can be influenced by particle size (Deng et al., 2017). For example, MPs measuring 8–10 μm are mostly located in the gills and intestines of crabs (Watts et al., 2014), MP 10 μm can be transported into the circulation of shellfish (Baber and Bartlett, 2015), MPs 5 μm can accumulate in the liver of fish zebra (Lu, et al., 2016). Although most research on the toxic effects of MPs has focused on aquatic organisms, studies documenting the potential health risks and tissue accumulation of MPs in mammals are lacking (Deng et al., 2017). Recently, a study measured the mass concentration of microplastics in human blood at concentrations as high as 1.6 $\mu\text{g}/\text{ml}$ (Leslie et al., 2022). Accumulation of MPs in tissues can cause various adverse effects, such as physical injury (De Stephanis et al., 2013), decreased eating activity (Gutow et al., 2014), inhibition of growth and development (Besseling et al., 2014), lack of energy (Cole et al., 2015), immune response (Avio et al., 2015), oxidative stress (Browne et al., 2013), neurotoxic response (Luís et al., 2015), metabolic disorders (Mattsson et al., 2015) and genotoxicity (Rochman et al., 2014). Therefore, data on MPs tissue accumulation in mammalian models would be highly desirable, but not for risk assessment of MPs in human health. We tested the *in vivo* effects of polyethylene (PE) microplastics with a size of 5 μm^2 by administering oral polyethylene microplastics (MP-PE) at a time. We assessed the toxicity effects in male white rats. Blood sampling was carried out to measure creatinine, SGOT, and SGPT before and after exposure to MP-PE to determine the impact more comprehensively of whether MP-PE caused damage to the kidneys and liver by histopathological examination. This study provides insight into the toxicity of MP-PE administered *in vivo* and its potential bioaccumulation in organs when administered acutely.

MATERIAL AND METHOD

The materials and methods used in this study were in the form of toxicity tests using male white mice, referring to the Regulation of the Head of the Food and Drug Supervisory Agency of the Republic of Indonesia number 7 of 2014 concerning guidelines for *in vivo* nonclinic toxicity testing,

for examination of blood samples and examination of kidney and liver organs histopathologically referring to the Ministry of Health, Republic of Indonesia in 2017 concerning medical laboratory technology.

Ingredients and solvents

Pure MP-PE particles were purchased from the industry. This MP-PE was sterilized first with distilled water and then mixed with 0.5% CMC Na solution so that it was easy to dissolve and administered to white mice. The 0.5% CMC Na solution was prepared by weighing 500 mg of CMC Na into 10 ml of hot distilled water, then leaving it for approximately 15 minutes until it was clear and shaped like gel. Next, it was stirred until it became a homogeneous mass and diluted in a volumetric flask with distilled water to a volume of 100 ml.

Experimental approach

Thirty mice were each assigned to five groups: Group 1, which was considered the control group; Group 2, which was exposed to 5 mg/kgBB MP-PE; Group 3, which received 50 mg/kgBB MP-PE; Group 4, which received 300 mg/kgBB MP-PE; and Group 5, which received 2000 mg/kgBB MP-PE. All mice were given this dose alone with an observation period of 14 days.

Clinical observation

Observation of animals, the presence of moribund or dead animals, and measurement of animal weight are carried out before exposure for single-dose toxicity studies. In addition, food consumption and drinking water are still provided after a single exposure and observation for the next 14 days.

Clinical pathology analysis

Clinical pathological analysis of creatinine

For quantitative determination in vitro of creatinine concentration in mice, plasma, or urine on the Konelab analyzer using the enzymatic method. All test results are interpreted considering the clinical context and examined using the Indiko Thermo scientific auto analyzer photometer (end point and colorimetric).

Clinical pathological analysis of ALT/GPT

For quantitative determination of alanine aminotransferase in vitro (L-Alanine:2-Oxoglutarate Aminotransferase (ALT) activity, EC 2.6.1.2) in human serum or plasma on Konelab Analyzer. All test results must be interpreted in relation to the clinical context and checked using the Indiko Thermo scientific auto analyzer: photometer (end point and colorimetric).

Clinical pathology analysis of AAST/GOT

For in vitro quantitative determination of aspartate aminotransferase (L-Aspartate: 2-Oxoglutarate Aminotransferase (AST) activity, EC 2.6.1.1) in rat serum or plasma on Konelab analyzer. All test results must be interpreted in relation to the clinical context and checked using the Indiko Thermo scientific auto analyzer: photometer (end point and colorimetric).

Statistic analysis

All haematology data, serum biochemistry, body weight, and organ data are presented as minimum, maximum, and mean \pm standard deviation (SD). Data that were not normally distributed were analyzed using the nonparametric unpaired Mann-Whitney test. A comparison of several groups is carried out using an analysis of variance with a post-test. According to Bonferroni. A p-value < 0.05 was considered statistically significant.

Histopathological analysis

Anatomical pathology preparations

Organ histology preparation begins with the organ fixation stage. Organ tissue is placed in a 10% buffered neutral formalin fixing solution for at least 24 hours. Fixation prevents post-mortem degeneration, kills microorganisms that may still be present, and stiffens the tissue so it can be easily cut. Organs that have been fixed are cut to a thickness of 5 mm and placed in a tissue cassette. Next, in the dehydration stage, the tissue pieces in a tissue cassette are placed in graded concentrations of alcohol (70% alcohol, 80% alcohol, 96% alcohol, absolute alcohol I, absolute alcohol II, absolute alcohol III for 30 minutes each) to remove the water content in the network. Next is the clearing stage; the tissue pieces in a tissue cassette are then placed in xylol solution for 2×30 minutes to remove the alcohol in the tissue. The

aim is to make the tissue more straightforward and transparent by filling it with liquid paraffin. Next is the impregnation stage. The tissue pieces are placed in liquid paraffin for 2 × 2 hours. Next is the embedding stage. The tissue pieces in the cassette are embedded in paraffin, which has a melting point of 560–580 °C. Wait until the paraffin becomes solid. Tissue embedded in solid paraffin was cut 4 µm thick with a microtome. The tissue pieces are attached to the glass object. The tissue on the glass object is heated to a temperature of 560–580 °C to melt and remove the remaining paraffin between the tissue, then rinsed with distilled water.

Tissue staining with HE

Sequentially, the tissue on the object glass is put in: Xylol for 1 minute, Xylol for 2 minutes, 100% alcohol for 2 minutes, Hematoxylin for 2 minutes, Aquades for 2 minutes, Eosin for 2 minutes, Aquades for 15 seconds, 80% alcohol for 15 seconds, 96% alcohol for 30 seconds, 100%

alcohol for 30 seconds, Xylol for 1 minute, Xylol for 1 minute, The tissue that has been coloured on the object glass is covered with a cover glass, that was previously dripped with entellan, which is a transparent adhesive. Determination of scoring disorders in the kidney and liver organs of male white rats

RESULTS AND DISCUSSION

Changes in body weight per level of MP-PE exposure in male white rats (*Rattus norvegicus*)

The acute administration of a single dose of MP-PE is presented here based on differences in body weight (BW) of mice over time to show at what dose changes in body weight occur based on the graph (Figure 1).

Figure 1 explains the changes in body weight of mice that were given a single exposure to MP-PE and

Table 1. Guide to kidney and liver disorders through scoring values

Body network	Wound	Score
Kidney	Swelling	Score 0: If no tubular cells are found to experience degeneration Score 1: If tubule cells are found to experience degeneration/cytoplasmic swelling in < 25% of the tubule cells Score 2: If tubule cells are found to experience degeneration/cytoplasmic swelling in 25–60% of the tubule cells Score 3: If tubule cells are found to experience degeneration/cytoplasmic swelling in > 60% of the tubule cells
	Inflammation	Score 0: If no inflammatory cells/plasma cells are found in the interstitial area Score 1: If you find a mild distribution of inflammatory cells, lymphocytes/plasma cells in the interstitial area Score 2: If moderate distribution of inflammatory cells, lymphocytes/plasma cells are found in the interstitial area Score 3: If a hard/diffuse distribution of inflammatory cells, lymphocytes/plasma cells are found in the interstitial area
	Necrosis	Score 0: If no tubular/glomerular cells are found experiencing necrosis Score 1: If tubular/glomerular cells are found that are experiencing necrosis
	Hyaline cast	Score 0: If no hyaline cast is found in the tubule lumen Score 1: If hyaline casts are found in the tubule lumen
	Fibrosis	Score 0: If no areas of fibrosis are found in the renal parenchyma Score 1: If an area of fibrosis is found in the renal parenchyma
Liver	Inflammation	Score 0: If no inflammatory cells/plasma cells are found in the liver portal area Score 1: If a mild distribution of inflammatory cells, lymphocytes/plasma cells are found in the hepatic portal area Score 2: If moderate distribution of inflammatory lymphocytes/plasma cells is found in the liver portal area Score 3: If a hard/diffuse distribution of inflammatory cells, lymphocytes/plasma cells are found in the liver portal area and extends to the liver lobule area
	Ballooning	Score 0: If no hepatocyte cells are found experiencing hydropic degeneration Score 1: If a distribution of hepatocyte cells is found experiencing mild hydropic degeneration Score 2: If you find a distribution of hepatocyte cells experiencing moderate hydropic degeneration Score 3: If a distribution of hepatocyte cells is found that has experienced severe hydropic degeneration or hepatocyte cells that are necrotic are found.
	Steatosis	Score 0: If no hepatocytes are found that have accumulated intracellular fat Score 1: If hepatocyte cells are found that have accumulated intracellular fat

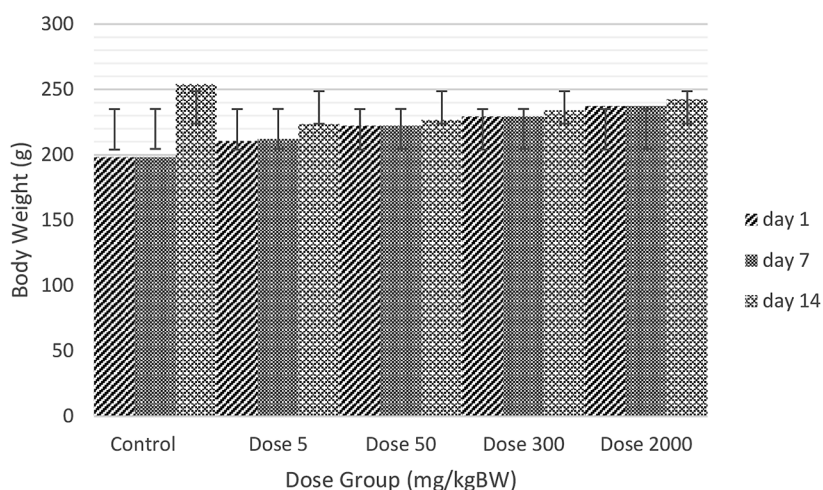


Figure 1. Mean and standard deviation of dose exposure to WB

then observed further for the next 14 days. In this single exposure, no mice were found to be sick or even dead in 50% of the total white mouse samples (LD50), so the LD50 value is pseudo and cannot be calculated because the mice did not get sick or even die, so this resulted in the mice not experiencing weight loss but instead an increase in body weight or in other words the acute dose of MP-PE in this study was in a safe condition for mouse metabolism such as the comparison of days 1 and 14 for a dose of 2000 mg/kgBW, it was seen that day 1 had a weight of 237.33 ± 8.779 then on day 14 it increased to 242.67 ± 10.231 , this also happened in all variations of the existing MP-PE dose (Figure 2).

MP-PE exposure to increased kidney and liver activity in male white rats (*Rattus norvegicus*)

Data was obtained from examining kidney activity (creatinine) obtained from rat serum before and after acute exposure to MP-PE. Then, the data was tested for statistical normality to decide the data distribution for further tests to determine the difference before and after acute exposure to MP-PE. PE on creatinine activity. Based on the data obtained, it can be seen that the number of samples in this study was > 30 samples, so the data

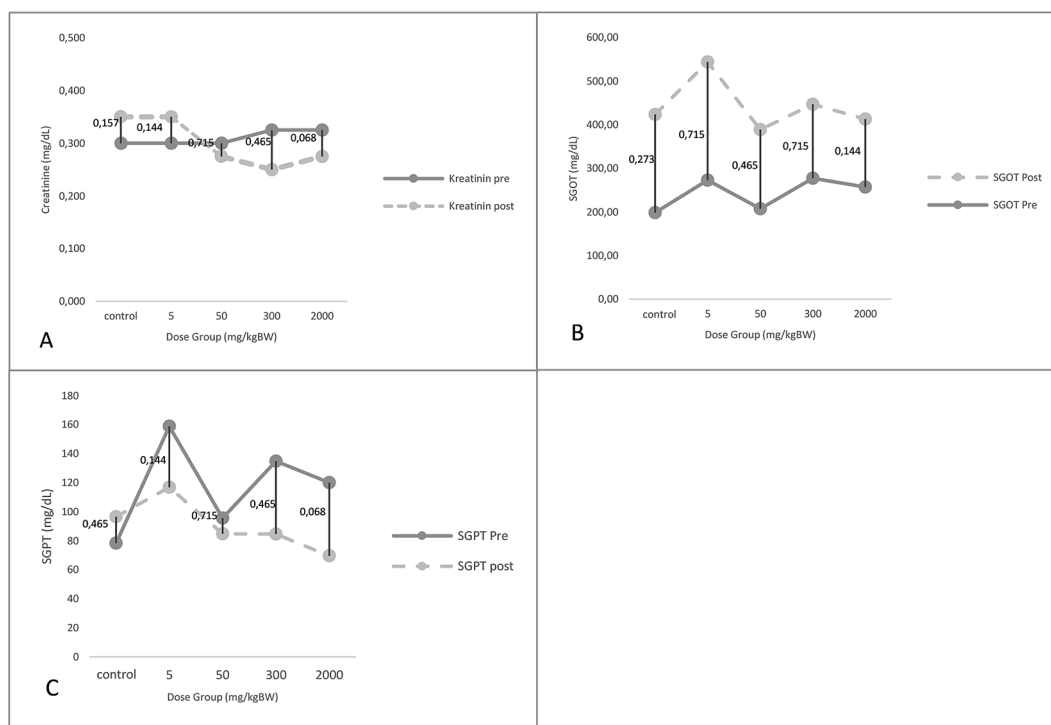


Figure 2. Difference test: (A) Pre and post creatinine per dose of MP-PE ($p < 0.05$); (B) Pre and post SGOT per dose of MP-PE ($p < 0.05$); (C) Pre and post SGPT per dose of MP-PE ($p < 0.05$)

normality test was chosen, namely using the Kolmogorov-Smirnov test. The data normality results show that the distribution of data from the kidney variables creatinine pre 0.000 and creatinine post 0.000 is not normally distributed ($p < 0.05$). Data were obtained from the results of serum examinations before and after exposure to various doses of MP-PE. These results are presented in a line diagram with each treatment group's average and standard deviation. The mean value and standard deviation of creatinine increased between before and after exposure to MP-PE doses starting from the control group, the low dose group of 5 mg/kgBW and the high dose group of 2000 mg/kgBW.

Different tests carried out on mice with groups exposed to the MP-PE dose on the results of kidney and liver activity, namely before and after giving MP-PE exposure, can be seen that overall, for the direct relationship between the two, no significant difference was found in the creatinine activity values before and post of each MP-PE exposure dose ($P < 0.05$), pre and post-SGOT activity of each MP-PE exposure dose ($P < 0.05$); and pre and post SGPT activity from each dose of MP-PE exposure ($P < 0.05$). Overall, this difference in the test shows that the role of MP-PE exposure at each dose is not significantly different in increasing kidney and liver activity (Figures 3–5).

Exposure to MP-PE given acutely with graded doses starting from a dose of 5 mg/kgBW to a dose of 2000 mg/kgBW had a significant impact

on increasing kidney activity with a p -value = 0.026 (Figure A), increasing SGOT liver activity with a p -value = 0.027 (image B), and increased SGPT activity with a p -value = 0.003 (image C). This is because MP-PE cannot be excreted in the urine but instead accumulates in the kidneys to increase kidney performance. In this case, the liver's performance has a detoxification role from toxins and free radicals, causing the liver's performance activity to increase, and ultimately, both organs experience an inflammatory phase.

Exposure to MP-PE doses on histopathological kidney and liver damage in male white rats (*Rattus norvegicus*)

This study's kidney and liver organ damage was reversible (fatty degeneration, congestion, inflammatory cell infiltration) and irreversible (necrosis). All treatments in various doses given in this study showed many mild, moderate, and severe changes, all of which can be seen in the scoring results and histopathological damage (Figure 6).

It was found that the overall dose showed abnormalities in the kidney organs through several scoring values (Table 1); the higher the dose, the higher the damage was caused. In the image of rat kidney damage (Figure 6), what was seen earlier was Swelling damage with a score of 2 in the 5–300 mg/kg BB dose group, where tubular

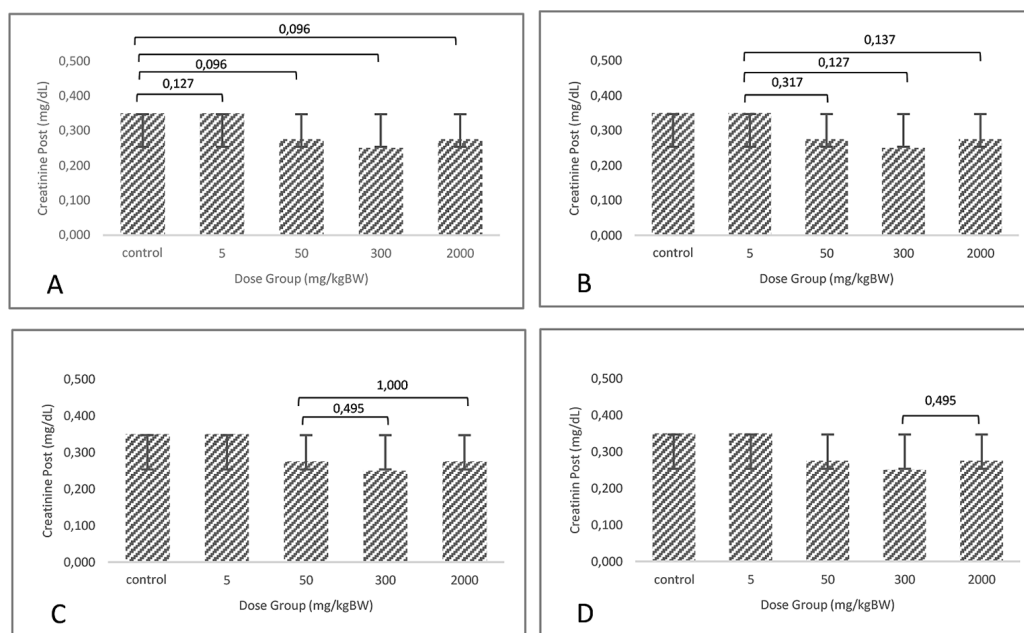


Figure 3. Post creatinine difference test between doses (A) control – 5, 50, 300, 2000 ($p > 0.05$); (B) 5– 50, 300, 2000 ($p > 0.05$); (C) 50–300, 2000 ($p > 0.05$); (D) 300–2000 ($p > 0.05$)

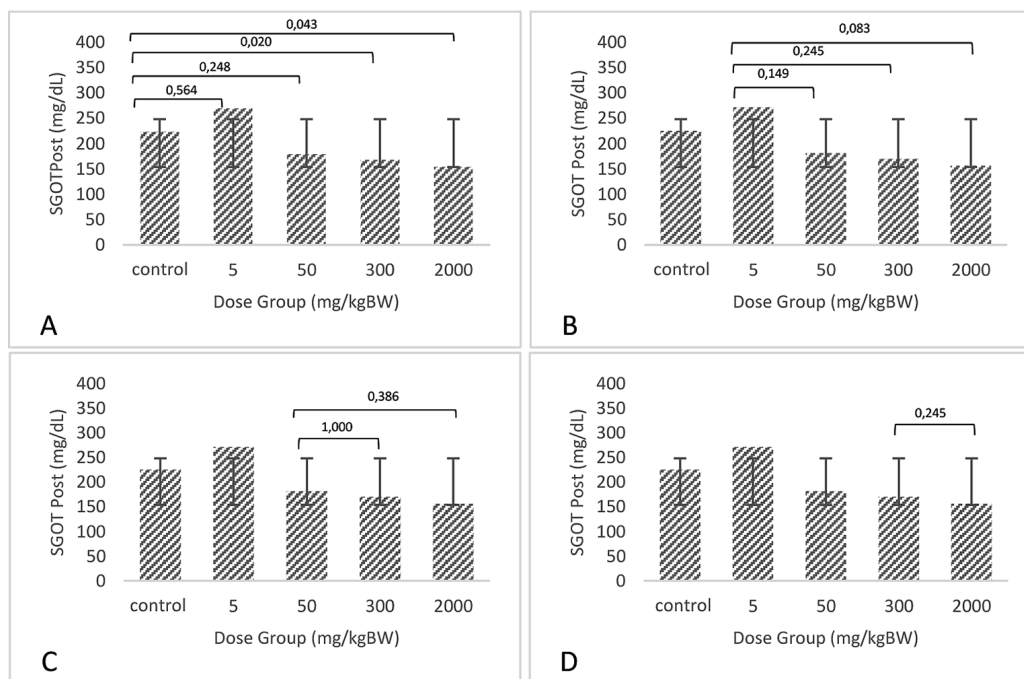


Figure 4. Post SGOT difference test between doses (A) control – 5, 50, 300, 2000 ($p > 0.05$); (B) 5 – 50, 300, 2000 ($p > 0.05$); (C) 50–300, 2000 ($p > 0.05$); (D) 300–2000 ($p > 0.05$)

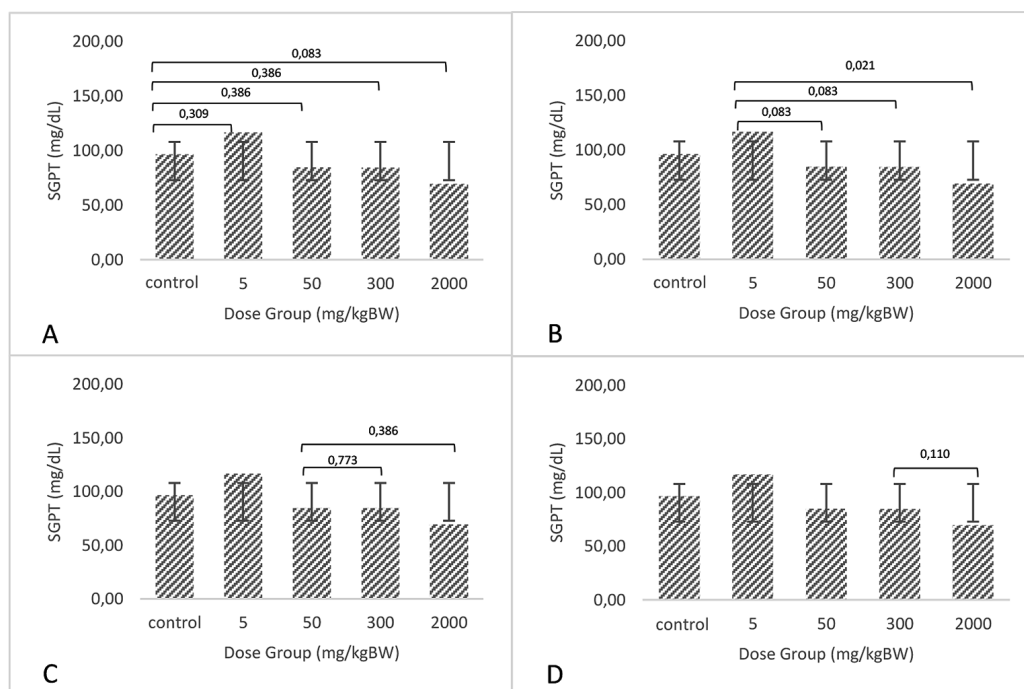


Figure 5. Post SGPT difference test between doses (A) control–5, 50, 300, 2000 ($p > 0.05$); (B) 5, 50, 300, 2000 ($p > 0.05$); (C) 50–300, 2000 ($p > 0.05$); (D) 300–2000 ($p > 0.05$)

cells were found to experience degeneration/cytoplasmic swelling at 25–60% and the percentage increased to > 60% of tubular cells with a score of 3, inflammatory damage also occurred at a dose of 5–300 mg/kgBW with a score of 2 where a moderate distribution of inflammatory

cells of lymphocytes/plasma cells was found in the interstitial area and increased to a score of 3 at a high dose of 2000 mg/kgBW with hard/diffuse distribution of lymphocytes/plasma cells in the interstitial area and hyaline cast damage occurred in all dose groups with a score of 1, namely the

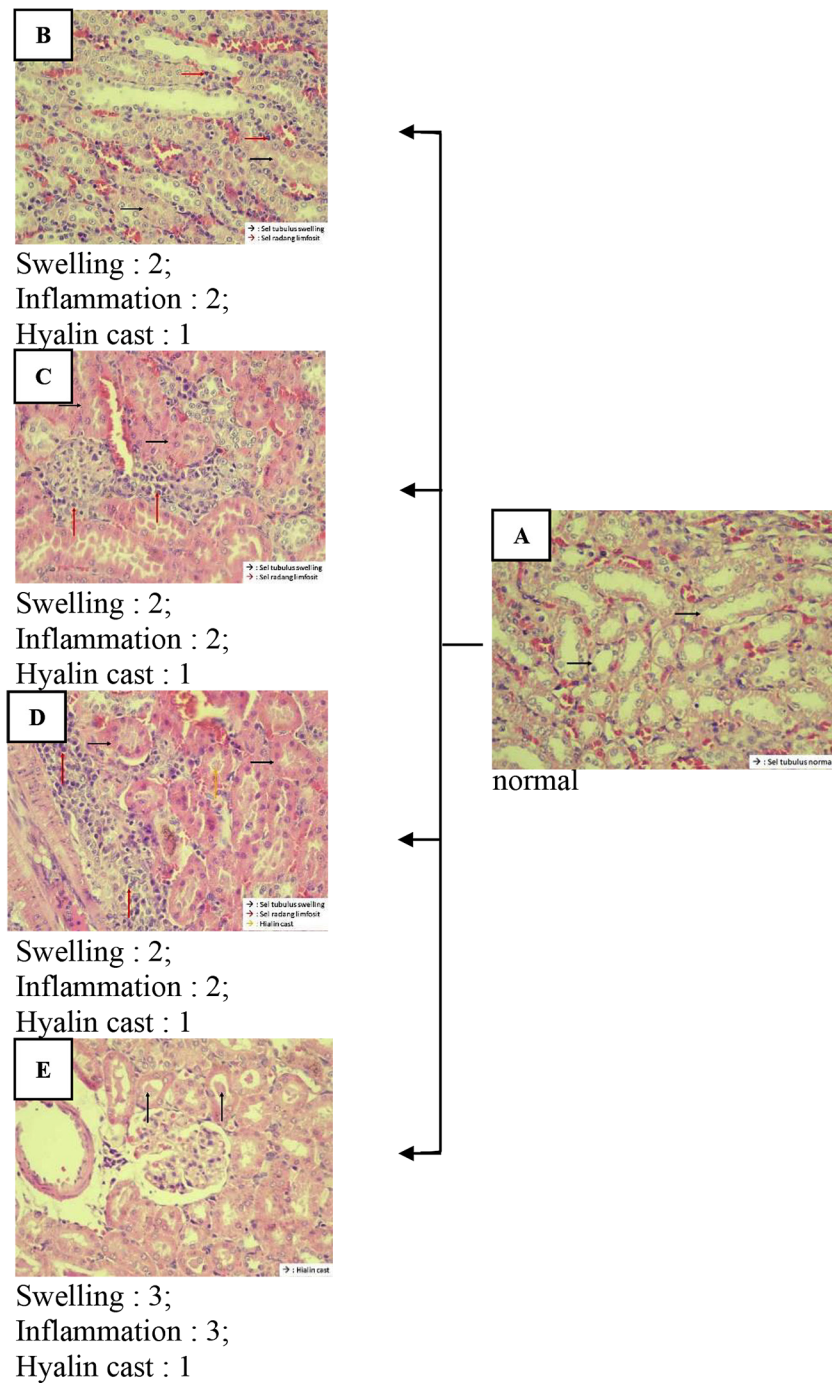


Figure 6. Histopathology of kidney tissue (A) control group; (B) dose of MP-PE 5 mg/kgBW; (C) dose of MP-PE 50 mg/kgBW; (D) dose of MP-PE 300 mg/kgBW; dose of MP-PE 2000 mg/kgBW

discovery of hyaline casts in the tubular lumen. The causes of this damage include toxic substances entering the body, where the function of the kidneys is to excrete metabolic waste. Damage to the kidneys caused by toxic substances can be identified through changes in the histological structure, including the occurrence of necrosis in cells, which is morphologically characterized by the destruction of the proximal tubule epithelial cells where the proximal tubule epithelial cells

are sensitive to anoxia and are easily destroyed if poisoning occurs due to residual metabolic waste excreted by the kidneys. So, histological changes in the kidneys can be confirmed because the number of compounds entering the body is also vast (Jannah and Budijastuti, 2022) (Figure 7). Based on scoring damage to the liver, by looking at the increase in serum SGOT and SGPT activity (Table 1), organ damage was visible, namely gradual inflammatory damage with a score of 1 at the

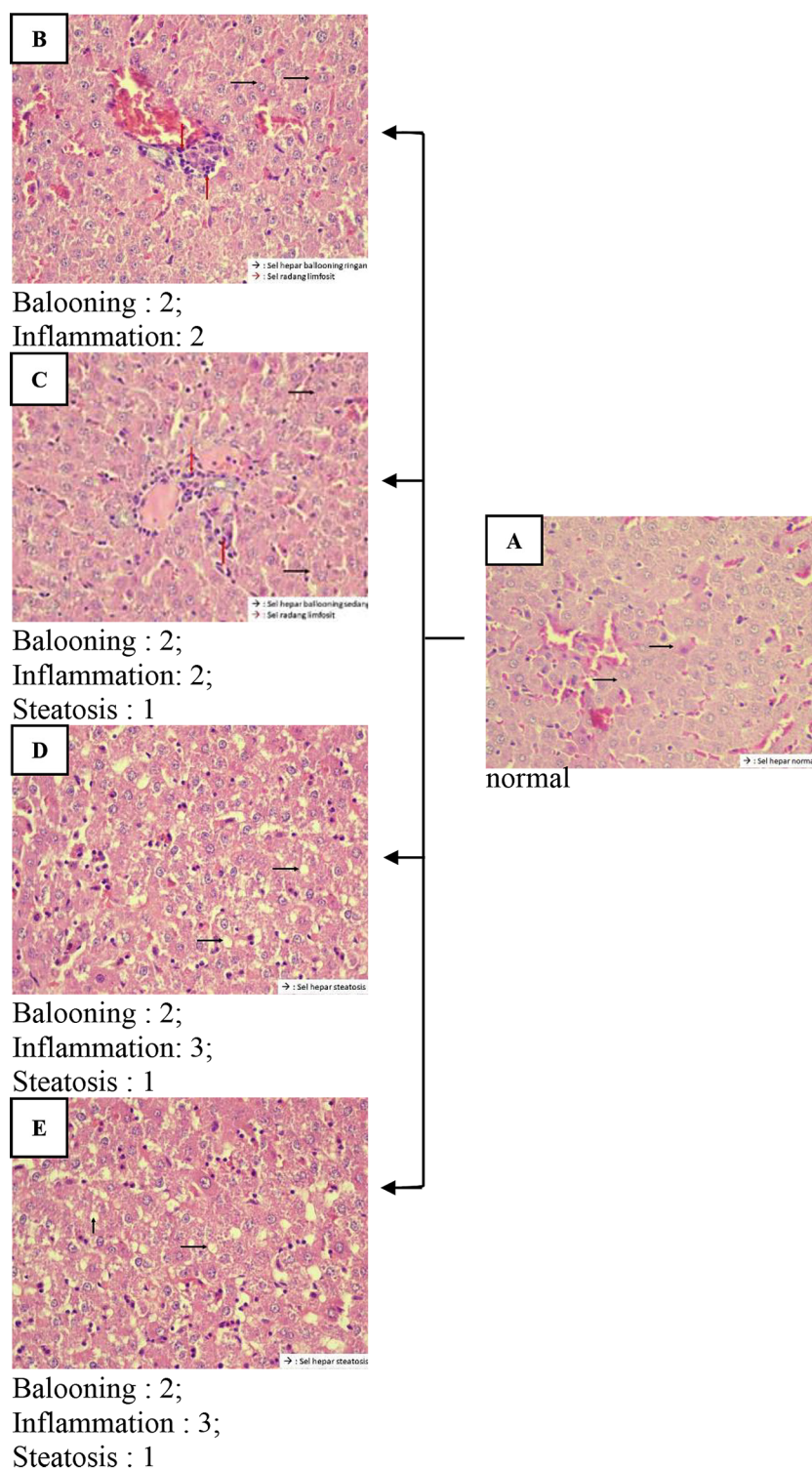


Figure 7. Histopathology of liver tissue (A) control group, (B) given with a dose of MP-PE (5 mg/kg), (C) given with a dose of MP-PE (50 mg/kg), (D) given with dose of MP-PE (300 mg/kg), (E) given a dose of MP-PE (2000 mg/kg)

control dose where light distribution of inflammatory lymphocytes/plasma cells was found in the liver portal area and increased to a score of 2 on the next dose where a moderate distribution of inflammatory lymphocytes/plasma cells was found in the hepatic portal area. Ballooning damage was

also found to be graded at low to high doses with a score of 1 in the control group, a score of 2 at doses of 5 and 50 mg/kgBW, a score of 3 at doses of 300 and 200 mg/kgBW where a score of 1 indicates that the distribution of degenerated hepatocyte cells was found. Mild hydropic, score two

if a distribution of hepatocyte cells experiencing moderate hydropic degeneration is found and score three if a distribution of hepatocyte cells experiencing severe hydropic degeneration or necrotic hepatocyte cells is found. The final damage is found at 50, 300 and 200 mg/ kgBB doses, with a score of 1, where hepatocytes have accumulated intracellular fat.

The damage to the liver is due to the active compounds that are entered orally and absorbed along the digestive tract, which are then distributed throughout the body through the blood. Most of these active compounds will then be neutralized in the liver. The liver plays a vital role in detoxification or neutralization because the liver can activate or deactivate active compounds that enter the body (Wahyuni et al., 2017). It then underlies that the liver histology changes after analysis were significantly different ($P < 0.05$). The results of weighing the average weight (Figure 1), through observations carried out for 14 days, showed that there were no test animals that experienced pain or suffering after giving MP-PE, so what was seen then was that there was no decrease in body weight, but on the contrary, namely an increase. The BW of the test animals, or in other words, the acute dose of microplastics in this study, was in a safe condition for rat metabolism so that it did not cause pain or suffering to the white rats. On the other hand, if the rats were sick, there was a possibility of a decrease in BW. It was done by other researchers where if the conditions were indicating an animal is in pain and suffering, it is generally accompanied by a body weight that has decreased by more than 20% or a body weight that has decreased by more than 25% during the period of toxicity, and usually, no food consumption. Test animals experienced fluctuating changes in body weight (Nurfaat et al., 2016).

Kidney and liver organs exposed to MP-PE can cause ROS (reactive oxygen species) effects. Apart from interpreting the data (Figure 2), we comprehensively analyzed the differences in liver and kidney serum test results before and after exposure to MP-PE (Figure 2). MP-PE alters energy and fatty acid metabolism. The accumulation of microplastics in the liver and kidneys has also been shown to increase the growth and accumulation of fat cells and disrupt energy balance, which in turn can affect metabolism and increase body weight. Additionally, plastic additives can contain harmful chemicals that can act as additional contaminants in microplastics. Many of these plastic additives,

including organotin, phthalates, bisphenols and toxic metals, affect the growth of fat cells and proteins that regulate lipid and glucose metabolism. Bisphenol A (BPA), commonly used to make certain types of plastic, is known to affect the body's endocrine system and hormonal balance, which can affect metabolism and weight gain.

ROS tend to obtain electrons from other substances, which makes free radicals reactive. The formation of ROS through the steps of reducing single oxygen to electrons occurs in mitochondrial cytochrome oxidase. The formation of ROS is influenced by cells experiencing inflammation, injury and infection by bacteria, viruses and other foreign materials. It can cause oxidative stress, which can cause cell and tissue damage.

If the analysis is continued on the aspect of the MP-PE type, the irregular surface, edges and shape of the particles will also trigger injury to surrounding cells, ultimately triggering local inflammation. Surrounding cells will initiate necrosis by releasing histamine, prostaglandins, and bradykinin (Wright and Kelly, 2017). The surrounding blood vessels will experience vasodilation to flow more blood, especially leukocyte cells, to the area (Deng et al., 2017). This process is acute inflammation, which aims to destroy, reduce or sequester the trigger that causes the injury (Deng et al., 2017). This acute inflammation is characterized by the release of basophils and lymphocytes (Prata et al., 2020). However, because microplastics are exogenous materials that leukocyte cells cannot destroy, the inflammation continues to become chronic until tissue damage occurs, characterized by the release of nitric oxide enzymes, lysosomal enzymes, neutrophils and macrophages. The results of this study show a trend of increasing blood basophils and neutrophils in the exposure group, along with increasing doses of exposure to polyethylene microplastics. It indicates the ongoing occurrence of acute and chronic inflammatory processes.

An increase occurs at the first exposure dose in the serum values of pre and post-renal activity after exposure to the MP-PE dose. It occurs because chemicals that are absorbed acutely with 24-hour exposure will not enter the urine but will be retained in the body, slowly settling in the body and affecting kidney function. It is the same as research on exposure to phosphate chemicals in white rats by (Turner et al., 2018). Phosphate chemicals absorbed and not excreted into the urine will be retained acutely in the body. As renal

function declines, the body may develop an adaptive mechanism whereby phosphate is rapidly removed from the circulation. At the same time, it is absorbed and deposited into tissues, effectively inhibiting increases in serum phosphate. Whether this is an active or passive process is unknown; however, blood vessels may act as deposition sites. This concept is supported by the finding that prolonged increased exposure to phosphate is an essential early factor in the development of vascular calcification *in vivo* and *in vitro* (Paloian and Giachelli, 2014). Previous research found that the microplastic size also had a significant difference in effect, even though the same size tested was polystyrene microplastic, and the research was carried out on the same human lung cell line. Research shows that both types of material (plastic) and size affect the organ lines in both the kidneys and lungs differently. It is also worth noting that many studies chose measures that are not found in our natural environment.

The damage caused by exposure to MP-PE is also based on research which found that it was confirmed that the accumulation of microplastics in rat kidneys caused histopathological damage, increased levels of endoplasmic reticulum stress markers, inflammatory markers, and nephrotoxicity (Nakamura et al., 2022). Furthermore, research by Goodman et al. regarding the effect of microplastics *in vitro* on embryonic kidney and liver cells shows that microplastics produce toxic effects on cell metabolism and cell interactions, one of which is a decrease in gene expression for antioxidant enzymes such as superoxide. Dismutase 2 (SOD2) and catalase (CAT) reduce the ability of the SOD2 and CAT enzymes to detoxify reactive oxygen species (ROS) and cause oxidative stress in cells so that cells experience damage (Goodman, et al., 2022).

Kidneys, one of the organs with the highest energy consumption rate in the body, are rich in mitochondria. ATP produced by mitochondria through oxidative phosphorylation serves as the primary energy source for the kidneys. Numerous studies have shown that mitochondrial function is impaired in various causes of acute kidney injury and chronic kidney disease. These histopathological changes could be the molecular basis for compensating renal structure and function caused by environmentally relevant exposure doses of MP-PE. It should be noted that when the MP-PE exposure dose increases, kidney mitochondria may become dysfunctional. In summary, this study

implies that mitochondrial dysfunction may be involved in the kidney damage caused by MP-PE, affecting the oxidative phosphorylation process.

The accumulation of MP-PE to increase liver activity is considered a consequence of liver disease, which can have acute and chronic impacts, so when the MP-PE dose is given acutely, there is undoubtedly a significant influence on the results of serum SGOT and SGPT with acute exposure, also liver disease will occur. Occurs if it is a complication. According to research conducted by Thomas Harvatics, et al, decreased liver function due to exposure to microplastics in the liver can be considered a severe consequence of spontaneous bacterial peritonitis (SBP), which generally occurs in the same way as microorganisms penetrate the intestine and transport to the liver. MP accumulation in the liver particles migrates through the intestinal wall and becomes hypertension (the leading cause of clinical complications of liver cirrhosis), which leads to subsequent intestinal disorders.

In this study, using histopathological tests, it was seen that various types of damage were visible microscopically in the kidneys and liver of white mice. In the same case, a recently published study found that including polystyrene microplastic MP in human blood samples can translocate to various organs in the body, such as the kidney or liver. The liver, which has a unique role in filtering toxins from the blood, is one of the first potential storage sites for microplastics when they enter the body through digestion.

Deng et al. stated that larger microplastic particles were found in the liver because it is the first-level filter organ compared to the kidneys. A diameter of $< 20 \mu\text{m}$ can penetrate various organs, such as the liver, kidneys, lungs, intestines and pancreas, while a size of $< 10 \mu\text{m}$ can penetrate various system barriers cell membranes, so it is found in all parts of the placenta and the brain. The toxic effects of polyethylene microplastics do not directly impact living creatures but need to be bioaccumulated to a specific dose.

Hwang et al. stated that the exposure dose is still controversial for researchers. However, a maximum particle size diameter of $20 \mu\text{m}$ has been declared to have the potential to cause health hazards to living creatures. Apart from the liver, the kidneys have an important role, whose primary function is to remove body toxins. They are another essential organ for the accumulation of microplastics. Microplastics filtered by the

liver and kidneys can collect in these organs and cause health problems. In vivo research on mice shows it harms the liver and kidneys. Accumulation of microplastics in the liver of mice causes adverse effects such as oxidative, inflammatory, energy changes, and liver and kidney damage. In this study, the accumulation of microplastics in rat kidneys affects weight loss, decreased kidney and liver function and histopathological damage.

CONCLUSIONS

In male white rats, polyethylene microplastics produce several toxins and cause impacts on the digestive system, kidney and liver, and histopathological abnormalities. These biochemical parameters can cause severe toxic effects on all organs through concentrations ranging from low doses to higher doses and for long periods with repeated exposure. The findings showed that the microplastic dose groups had a damaging effect on kidney and liver organ cells, reflecting the harmful impact of these dose groups on human health. The current study can initiate future comprehensive studies to determine the harmful dose of exposure to microplastics, especially polyethylene. Research on animals has been reviewed and approved by the Health Research Ethics Committee of the Faculty of Public Health, Airlangga University with No: 57/EA/KEPK/2021.

REFERENCES

- Amato-Lourenço LF, Carvalho-Oliveira R, Júnior GR, Dos Santos Galvão L, Ando RA, Mauad T. (2021). Presence of airborne microplastics in human lung tissue. *J Hazard Mater*. 15; 416, 126124. <https://doi.org/10.1016/j.jhazmat.2021.126124>
- Andrady, A.L. (2011). Microplastics in the marine environment, *Marine Pollution Bulletin*, 62(8), 1596–1605. <https://doi.org/10.1016/j.marpolbul.2011.05.030>
- Avio, C. G., Gorbi, S., Milan, M., Benedetti, M., Fattorini, D., D'Errico, G., Paoletto, M., Bargelloni, L., & Regoli, F. (2015). Pollutants bioavailability and toxicological risk from microplastics to marine mussels. *Environmental Pollution*, 198, 211–222. <https://doi.org/10.1016/j.envpol.2014.12.021>
- Banerjee, A. and Shelver, W.L. (2021). Micro- and nanoplastic induced cellular toxicity in mammals: A review, *Science of the Total Environment*, 755, 142518. <https://doi.org/10.1016/j.scitotenv.2020.142518>
- Besseling, E., Wang, B., Lüring, M., Koelmans, A.A. 2021. Nanoplastic affects growth of *S. obliquus* and reproduction of *D. magna*. *Environ Sci Technol*. 20, 12336–43. <https://doi.org/10.1021/es503001d>
- Browne, M.A, Niven, S.J., Galloway, T.S., Rowland, S.J., Thompson, R.C. (2013). Microplastic moves pollutants and additives to worms, reducing functions linked to health and biodiversity. *Curr Biol*. 23(23), 2388–92. <https://doi.org/10.1016/j.cub.2013.10.012>
- Cole, M., Lindeque, P., Fileman, E., Halsband, C., Galloway, T.S. (2015). The impact of polystyrene microplastics on feeding, function and fecundity in the marine copepod *Calanus helgolandicus*, *Environmental Science and Technology*, 49(2), 1130–1137. <https://doi.org/10.1021/es504525u>
- Deng, Y., Zhang, Y., Lemos, B., Ren, H. (2017). Tissue accumulation of microplastics in mice and biomarker responses suggest widespread health risks of exposure, *Scientific Reports*, 7(March), 1–10. <https://doi.org/10.1038/srep46687>
- Goodman, K.E., Hua, T. and Sang, Q.X.A. (2022). Effects of polystyrene microplastics on human kidney and liver cell morphology, cellular proliferation, and metabolism, *ACS Omega*, 7(38), 34136–34153. Available at: <https://doi.org/10.1021/acsomega.2c03453>
- Guo, J.J., Huang, X.P., Xiang, L., Wang, Y.Z., Li, Y.W., Li, H., Cai, Q.Y., Mo, C.H., Wong, M.H. (2020). Source, migration and toxicology of microplastics in soil, *Environment International*, 137, 105263. <https://doi.org/10.1016/j.envint.2019.105263>
- Hämer, J., Gutow, L., Köhler, A., Saborowski, R. (2014). Fate of microplastics in the marine isopod *Idotea emarginata*, *Environmental Science and Technology*, 1–15.
- Horvatits, T., Tamminga, M., Liu, B., Sebode, M., Carambia, A., Fischer, L., Püschel, K., Huber, S., Fischer, E.K. (2022). Microplastics detected in cirrhotic liver tissue, *eBioMedicine*, 82(22), 1–21. <https://doi.org/10.1016/j.ebiom.2022.104147>
- Hou, B., Wang, F., Liu, T., Wang, Z. (2021). Reproductive toxicity of polystyrene microplastics: In vivo experimental study on testicular toxicity in mice, *Journal of Hazardous Materials*, 405(June), 124028. <https://doi.org/10.1016/j.jhazmat.2020.124028>
- Jannah, D.R. and Budijastuti, W. (2022). Gambaran Histopatologi Toksisitas Ginjal Tikus Jantan (*Rattus norvegicus*) yang Diberi Sirup Umbi Yakon (*Smalanthus sonchifolius*) Histopatological Overview Kidneys Toxicity of A Male Rat (*Rattus norvegicus*) Being Given Yakon Tuber *Smalanthus sonchifolius*, *Lentera Bio*, 11(2), 238–246.
- Kik, K., Bukowska, B. and Sicińska, P. (2020).

- Polystyrene nanoparticles: Sources, occurrence in the environment, distribution in tissues, accumulation and toxicity to various organisms, *Environmental Pollution*, 262. <https://doi.org/10.1016/j.envpol.2020.114297>
16. Leslie H.A., van Velzen M.J.M., Brandsma S.H., Vethaak A.D., Garcia-Vallejo J.J., Lamoree M.H. (2022). Discovery and quantification of plastic particle pollution in human blood, *Environment International*, 163, 107199. <https://doi.org/10.1016/j.envint.2022.107199>
 17. Lu, F., Langenbacher, A.D. and Chen, J.N. (2016). Transcriptional regulation of heart development in zebrafish, *Journal of Cardiovascular Development and Disease*, 3(2). <https://doi.org/10.3390/jcdd3020014>
 18. Luís, L.G., Ferreira, P., Fonte, E., Oliveira, M., Guilhermino, L. (2015). Does the presence of microplastics influence the acute toxicity of chromium(VI) to early juveniles of the common goby (*Pomatoschistus microps*)? A study with juveniles from two wild estuarine populations, *Aquatic Toxicology*, 164, 163–174. <https://doi.org/10.1016/j.aquatox.2015.04.018>
 19. Mattsson, K., Ekvall, M.T., Hansson, L.A., Linse, S., Malmendal, A., Cedervall, T. (2015). Altered behavior, physiology, and metabolism in fish exposed to polystyrene nanoparticles, *Environmental Science and Technology*, 49(1), 553–561. <https://doi.org/10.1021/es5053655>
 20. Nakamura, J.S., Kim, E.S., Rentscher, K.E., Bower, J.E., Kuhlman, K.R. (2022). Early-life stress, depressive symptoms, and inflammation: the role of social factors., *Aging & mental health*, 26(4), 843–851. <https://doi.org/10.1080/13607863.2021.1876636>
 21. Nelms, S.E., Galloway, T.S., Godley, B.J., Jarvis, D.S., Lindeque, P.K. (2018). Investigating microplastic trophic transfer in marine top predators, *Environmental Pollution*, 238, 999–1007. <https://doi.org/10.1016/j.envpol.2018.02.016>
 22. Nugrahapraja, H., Sugiyo, P.W.W., Putri, B.Q., Ni'matuzahroh, F., Huang, L., Hafza, N., Götz, F., Santoso, H., Wibowo, A.T., & Luqman, A. (2022). Effects of microplastic on human gut microbiome: detection of plastic-degrading genes in human gut exposed to microplastics—preliminary study, *Environments - MDPI*, 9(11). <https://doi.org/10.3390/environments9110140>
 23. Nurfaat, D.L. and Indriyati, W. (2016). Acute toxicity test of ethanol extract of mango misletoe (*Dendrophthoe petandra*) to Strain of Swiss Webster Mice, *Ijpest*, 3(2).
 24. Opinion, S. (2011). Scientific opinion on epizootic ulcerative syndrome, *EFSA Journal*, 9(10). <https://doi.org/10.2903/j.efsa.2011.2387>
 25. Paloian, N.J. and Giachelli, C.M. (2014). A current understanding of vascular calcification in CKD., *American journal of physiology. Renal physiology*, 307(8), F891–900. <https://doi.org/10.1152/ajprenal.00163.2014>
 26. Prata, J.C., da Costa, J.P., Lopes, I., Duarte, A.C., Rocha-Santos, T. (2020). Environmental exposure to microplastics: An overview on possible human health effects., *The Science of the total environment*, 702, 134455. <https://doi.org/10.1016/j.scitotenv.2019.134455>
 27. Ragusa, A., Svelato, A., Santacroce, C., Catalano, P., Notarstefano, V., Carnevali, O., Papa, F., Rongioletti, M.C.A., Baiocco, F., Draghi, S., D'Amore, E., Rinaldo, D., Matta, M., Giorgini, E. (2021). Plasticenta: First evidence of microplastics in human placenta, *Environment International*, 146, 106274. <https://doi.org/10.1016/j.envint.2020.106274>
 28. Reddy, M.M., Vivekanandhan, S., Misra, M., Bhatia, S.K., & Mohanty, A.K. (2013). Biobased plastics and bionanocomposites: Current status and future opportunities, *Progress in Polymer Science*, 38(10–11), 1653–1689. <https://doi.org/10.1016/j.progpolymsci.2013.05.006>
 29. Rochman, C.M., Kurobe, T., Flores, I., The, S.J. (2014). Early warning signs of endocrine disruption in adult fish from the ingestion of polyethylene with and without sorbed chemical pollutants from the marine environment, *Science of the Total Environment*, 493, 656–661. <https://doi.org/10.1016/j.scitotenv.2014.06.051>
 30. Saha, S., Laforsch, C., Ramsperger, A., & Niebel, D. (2023). Microplastic and dermatological care, *Dermatologie*, 74(1), 27–33. <https://doi.org/10.1007/s00105-022-05035-z>
 31. Shen, T., Zhang, W., Wang, Y., Li, H., Wu, J., Wang, Q., Qin, L., Zhang, L., Liu, C., & Li, R. (2023). Relevant doses on the structure, function, and transcriptome of the Kidney in Mice. *Molecules*, 28(20), 7104. <https://doi.org/10.3390/molecules28207104>
 32. Sincihu, Y. (2022). Dampak pemberian mikroplastik poliethilen peroral terhadap hitung jenis sel leukosit darah Rattus norvegicus strain Wistar., *Medical Technology and Public Health Journal*, 6, 1–10. <https://doi.org/10.33086/mtphj.v6i1.2611>
 33. Statista Research Departement. (2023). Annual production of plastics worldwide from 1950 to 2021(in million metric tons), *Statista*, 2021, 24–27.
 34. de Stephanis, R., Giménez, J., Carpinelli, E., Gutierrez-Exposito, C., Cañadas, A. As main meal for sperm whales: plastics debris. (2013). As main meal for sperm whales: Plastics debris, *Marine Pollution Bulletin*, 69(1–2), 206–214. <https://doi.org/10.1016/j.marpolbul.2013.01.033>
 35. Turner, A.C., Kraev, I., Stewart, M.G., Stramek, A., Overton, P.G., Dommett, E.J. (2018). Chronic amphetamine enhances visual input to and suppresses visual output from the superior colliculus

- in withdrawal, *Neuropharmacology*, 138, 118–129. <https://doi.org/10.1016/j.neuropharm.2018.05.033>
36. Uurasjärvi, E., Sainio, E., Setälä, O., Lehtiniemi, M., Koistinen, A. (2021). Validation of an imaging FTIR spectroscopic method for analyzing microplastics ingestion by Finnish lake fish (*Perca fluviatilis* and *Coregonus albula*), *Environmental Pollution*, 288(July). <https://doi.org/10.1016/j.envpol.2021.117780>
37. Vianello, A., Jensen, R.L., Liu, L., Vollertsen, J. (2019). Simulating human exposure to indoor airborne microplastics using a Breathing Thermal Manikin, *Scientific Reports*, 9(1), 1–11. <https://doi.org/10.1038/s41598-019-45054-w>
38. Wahyuni, F.S., Putri, I.N. and Arisanti, D. (2017). Uji toksisitas subkronis fraksi etil asetat kulit buah asam kandis (*Garcinia cowa* Roxb) terhadap Fungsi Hati dan Ginjal Mencit Putih Betina, *Jurnal Sains Farmasi & Klinis*, 3(2), 202. <https://doi.org/10.29208/jsfk.2017.3.2.126>
39. Watts, A.J., Lewis, C., Goodhead, R.M., Beckett, S.J., Moger, J., Tyler, C.R., Galloway, T.S. (2014). Uptake and retention of microplastics by the shore crab *carcinus maenas*, *Environmental Science and Technology*, 48(15), 8823–8830. <https://doi.org/10.1021/es501090e>
40. Wright, S.L. and Kelly, F.J. (2017). Plastic and human health: a micro issue?, *Environmental science & technology*, 51(12), 6634–6647. <https://doi.org/10.1021/acs.est.7b00423>
41. Yee, M.S., Hii, L.W., Looi, C.K., Lim, W.M., Wong, S.F., Kok, Y.Y., Tan, B.K., Wong, C.Y., Leong, C.O. (2021). Impact of microplastics and nanoplastics on human health, *Nanomaterials*, 11(2), 1–23. <https://doi.org/10.3390/nano11020496>
42. Zhang, Z., Chen, W., Chan, H., Peng, J., Zhu, P., Li, J., Jiang, X., Zhang, Z., Wang, Y., Tan, Z., Peng, Y., Zhang, S., Lin, K., Yung, K.K. (2024). Polystyrene microplastics induce size-dependent multi-organ damage in mice: Insights into gut microbiota and fecal metabolites, *Journal of Hazardous Materials*, 461(January), 1–6. <https://doi.org/10.1016/j.jhazmat.2023.132503>